



Review

The functional neuroanatomy of depression: Distinct roles for ventromedial and dorsolateral prefrontal cortex

Michael Koenigs^{a,*}, Jordan Grafman^b

^a Department of Psychiatry, University of Wisconsin-Madison, 6001 Research Park Blvd, Madison, WI 53719, USA

^b Cognitive Neuroscience Section, National Institute of Neurological Disorders and Stroke, National Institutes of Health, 10 Center Drive, MSC 1440, Bethesda, MD 20892-1440, USA

ARTICLE INFO

Article history:

Received 4 February 2009

Accepted 3 March 2009

Available online 17 March 2009

Keywords:

Depression

Ventromedial prefrontal cortex

Dorsolateral prefrontal cortex

ABSTRACT

A primary aim in the neuroscientific study of depression is to identify the brain areas involved in the pathogenesis of symptoms. In this review, we describe evidence from studies employing various experimental approaches in humans (functional imaging, lesion method, and brain stimulation) that converge to implicate the ventromedial and dorsolateral sectors of prefrontal cortex as critical neural substrates for depression, albeit with distinct functional contributions. The putative roles of ventromedial and dorsolateral prefrontal cortex in depression are discussed in light of the results.

© 2009 Elsevier B.V. All rights reserved.

Contents

1. Introduction	239
2. Neuroanatomy of PFC: dorsolateral and ventromedial sectors	239
3. Functional imaging studies	240
4. Lesion patient studies	240
5. Brain stimulation studies	242
6. Discussion: roles of dlPFC and vmPFC in depression	242
7. Summary and conclusion	243
Acknowledgement	243
References	243

1. Introduction

Depression is one of the most widespread and debilitating forms of mental illness. Characterized by a variety of symptoms (behavioral, affective, cognitive, and somatic) and a high risk of relapse/recurrence, major depressive episodes often do not resolve to a complete and sustained recovery, even with intensive psychiatric care. A concerted research effort has aimed to elucidate the biological underpinnings of the disorder, and ultimately develop more effective treatments. To this end, numerous studies have sought to identify the key brain areas involved in the pathogenesis of depressive symptoms. In particular, the involvement of prefrontal

cortex has been a major focus [1–3]. In this article, we review neuroscientific evidence indicating that distinct subregions of prefrontal cortex play critical roles in the development (and treatment) of depression.

2. Neuroanatomy of PFC: dorsolateral and ventromedial sectors

Perhaps the most widely accepted division of prefrontal cortex, based on anatomical connectivity and functional specialization, is between the dorsolateral and ventromedial sectors [4–6]. The vmPFC includes the ventral portion of the medial prefrontal cortex (below the level of the genu of the corpus callosum) and medial portion of the orbital surface (approximately the medial one-third of the orbitofrontal cortex in each hemisphere) (Fig. 1A). Targets of vmPFC projections include the hypothalamus and periaqueductal gray, which mediate the visceral autonomic activity associated

* Corresponding author. Tel: +1 608 263 1679; fax: +1 608 263 9340.

E-mail addresses: mrkoenigs@wisc.edu (M. Koenigs), grafmanj@ninds.nih.gov (J. Grafman).

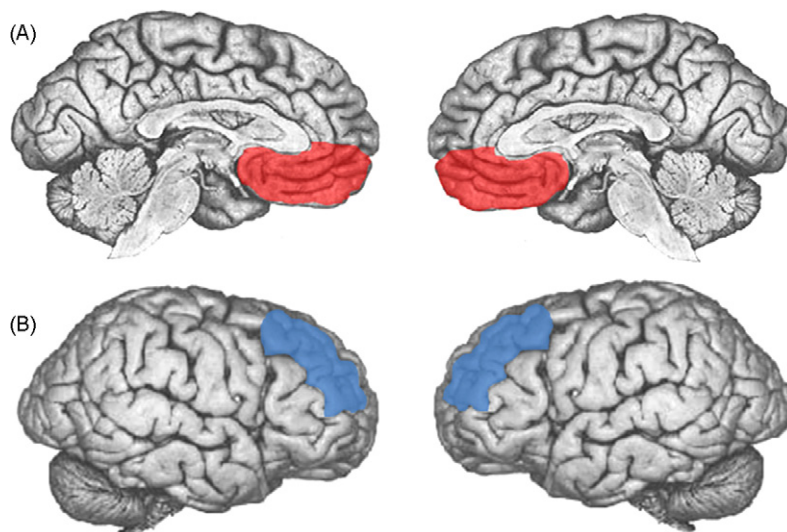


Fig. 1. (A) Depiction of vmPFC (in red) in midline views of each hemisphere. (B) Depiction of dlPFC (in blue) in lateral views of each hemisphere (for interpretation of the references to color in this figure legend, the reader is referred to the web version of the article).

with emotion, and the ventral striatum, which signals reward and motivational value. In addition, vmPFC has dense reciprocal connections with the amygdala, which is involved in threat detection and fear conditioning [7]. By contrast, the dlPFC, which includes portions of the middle and superior frontal gyri on the lateral surface of the frontal lobes (Fig. 1B), receives input from specific sensory cortices, and has dense interconnections with premotor areas, the frontal eye fields, and lateral parietal cortex [8]. The distinct patterns of connectivity in these two regions of PFC suggest disparate functionality. Indeed, dlPFC has primarily been associated with “cognitive” or “executive” functions, whereas vmPFC is largely ascribed “emotional” or “affective” functions. In the following sections, we describe human neuroscientific data that implicates each area in the pathophysiology of depression. We conclude with speculation on how the function of each area may be related to depression.

3. Functional imaging studies

Several types of functional imaging studies have been employed to identify brain areas involved in depression. The earliest functional imaging studies of depression compared the resting state brain activity (e.g. blood flow or glucose metabolism) of depressed patients to that of non-depressed comparison subjects. This type of study identifies regional abnormalities in resting brain activity associated with depression. Results from these studies associate depression with abnormally high levels of vmPFC activity [9–12], but abnormally low levels of dlPFC activity [10,13,14].

A second type of functional imaging study identifies areas of the brain where changes in activity are associated with recovery from depression, as in response to psychotherapy or antidepressant medication. In these studies, recovery from depression is associated with increased activity in dlPFC, but decreased activity in vmPFC [12,15–17].

A third, more recent, type of functional imaging study compares task-related brain activations (blood flow) of depressed patients to that of non-depressed comparison subjects. Data from these studies demonstrate that depressed patients exhibit greater task-related activation in dlPFC during tests of working memory and cognitive control when performance is matched to non-depressed subjects [18,19]. In light of the resting state data indicating dlPFC hypoactivity in depression, these results suggest dysfunction (or at least inefficiency) in the dlPFC of depressed patients.

In sum, the functional imaging studies converge to suggest that depression is associated with seemingly opposite activity profiles in vmPFC and dlPFC. vmPFC is hyperactive at rest and decreases in activity during remission of symptoms, whereas the dlPFC is hypoactive at rest and increases in activity during remission of symptoms. These imaging data hint that an imbalance in vmPFC/dlPFC activity may contribute to depression. However, the correlative nature of functional imaging data precludes any causal inference. In other words, functional imaging data alone cannot adjudicate whether the abnormal activity profiles observed in dlPFC and vmPFC are a cause or consequence of the disorder. In order to determine whether vmPFC and dlPFC play a causal role in depression, one must assess whether direct alterations in the function of the relevant brain areas affects the depressive symptoms. In the following two sections, we describe data from studies employing such methods.

4. Lesion patient studies

The “lesion method” refers to an approach whereby a focal area of brain damage is associated with the development of a change in some aspect of cognition or behavior, and then an inference is made that the damaged brain region is a critical part of the neural substrate for the altered function. That is, unlike functional imaging data, lesion data reveal causality—damage to a particular brain area *causes a change* in a particular function.

In a recent study using the lesion method [20], we directly addressed the question of whether vmPFC and/or dlPFC play a critical role in the development of depression. If the vmPFC hyperactivity and dlPFC hypoactivity revealed by functional imaging studies are indeed causally involved in the pathogenesis of depression, then damage to either area would presumably affect the development of depression, but with opposite effects. More specifically, vmPFC lesions would confer resistance to depression, whereas dlPFC lesions would confer vulnerability to depression. To test this hypothesis, we studied two populations of brain lesion patients. One population was the Vietnam Head Injury Study (VHIS), which consists entirely of male Vietnam veterans who suffered penetrating head injuries during combat. The other population was the University of Iowa Neurological Patient Registry, which consists of men and women who primarily suffered strokes, aneurysms, or neurosurgical resections. Both patient registries included multiple cases of focal, bilateral vmPFC lesions ($n = 7$ in the VHIS; $n = 12$ in

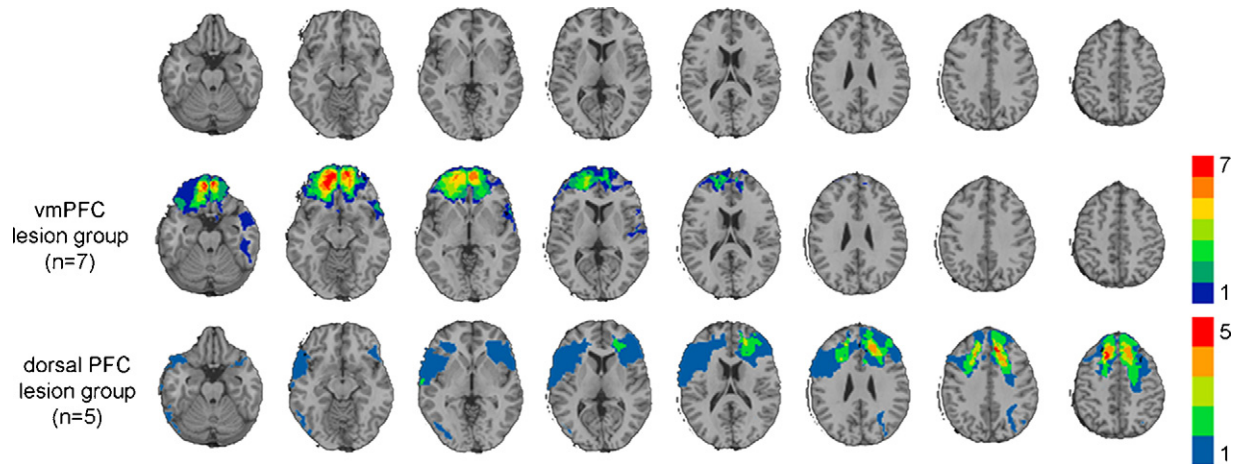


Fig. 2. Lesion overlaps of VHIS patients with bilateral vmPFC or dIPFC damage. Color indicates the number of overlapping lesions at each voxel. Top row: Axial slices of a normal healthy brain, for reference. Second row: Lesion overlap for the vmPFC lesion group. Third row: Lesion overlap for the dorsal PFC lesion group (for interpretation of the references to color in this figure legend, the reader is referred to the web version of the article).

the Iowa sample; Fig. 2). The VHIS also included a rare group of lesion patients whose brain damage included dIPFC in both hemispheres (along with the intervening dorsomedial PFC; $n=5$; Fig. 2). In both patient populations, depression was assessed with a self-report scale for the severity of specific symptoms of depression.

The depression scores of the vmPFC and dIPFC patients were compared to those of patients with lesions that did not involve PFC ($n=101$ in the VHIS; $n=238$ in the Iowa sample). In accord with our predictions based on the neuroimaging data, we found that the patients with bilateral vmPFC lesions had significantly lower levels

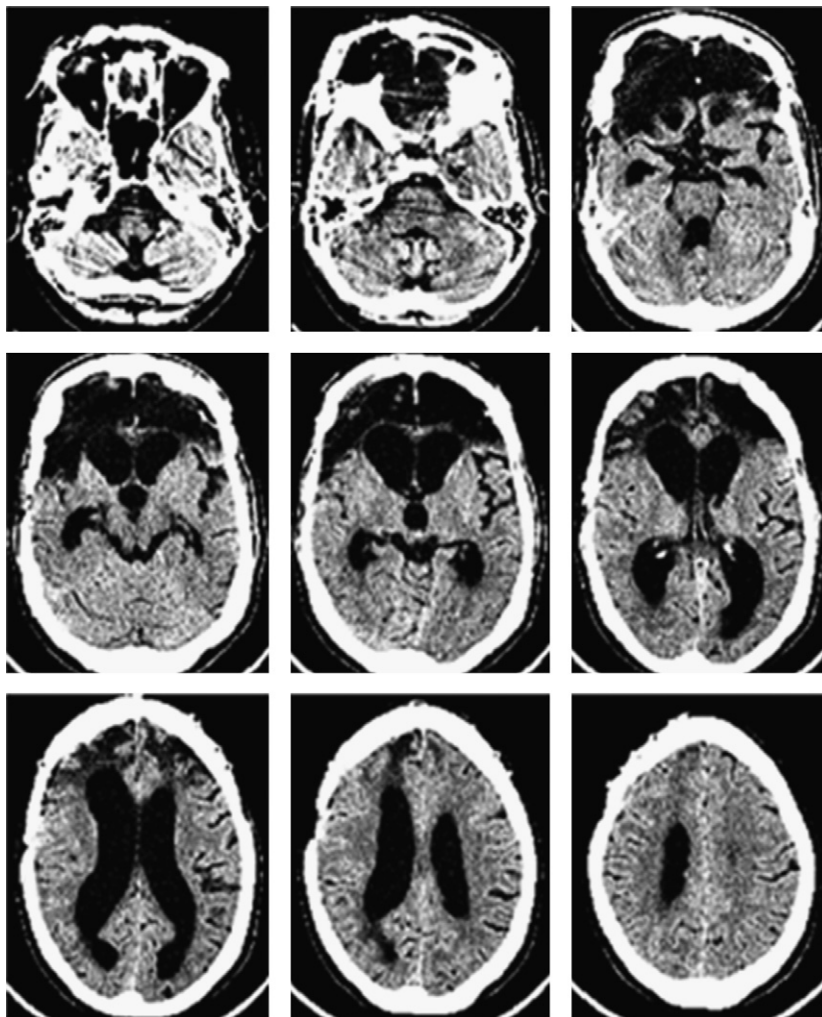


Fig. 3. CT image (axial slices) of patient experiencing depression alleviation following suicide attempt. Ventral PFC is almost entirely destroyed, including vmPFC bilaterally (top row), whereas dorsal PFC is largely intact (bottom row).

of depression, whereas bilateral dorsal PFC lesions (involving dlPFC in both hemispheres) had significantly higher levels of depression.

In addition, we identified a separate patient in the Iowa registry who represents an intriguing case of an apparent alleviation of severe depression following a bilateral vmPFC lesion. This patient was being treated for depression when she attempted suicide by means of a gunshot to the head. The gunshot destroyed most of ventral PFC, including vmPFC bilaterally, but left intact most of dorsal PFC (Fig. 3). The patient's neuropsychologist, neurosurgeon, and long-term boyfriend all remarked that her depression was markedly diminished following the brain injury, and the patient herself reported a complete absence of sadness or suicidal ideation. This case bears remarkable resemblance to a previously reported case [21], in which a 33-year old man attempted suicide with a crossbow, inflicting severe damage within vmPFC but sparing dlPFC. The case report states that following the vmPFC injury he was "indifferent to his situation and inappropriately cheerful". Together, these two extraordinary cases underscore the importance of vmPFC in mediating depressive symptoms.

The recent studies reporting diminished depression subsequent to vmPFC lesions echo the findings from a large clinical literature on the use of neurosurgery to treat severe depression (so-called "psychosurgery"). Procedures that induce damage to vmPFC and/or its white matter connections have been reported to be efficacious in alleviating depression. In one such procedure, known as "subcaudate tractotomy", the white matter within posterior vmPFC, which connects vmPFC with subcortical structures, is lesioned bilaterally [22,23]. Among the hundreds of cases of severe depression that have undergone subcaudate tractotomy, a majority have exhibited a significant reduction of symptoms [23–25].

In sum, human lesion studies have proven to be an indispensable means of determining causality with respect to the neural underpinnings of depression. And although the surgical introduction of brain lesions has been effective in treating many cases of severe depression, there are clearly significant drawbacks and limitations to this procedure that invite the development of alternative treatments.

5. Brain stimulation studies

In recent years, the exogenous stimulation of specific neuroanatomical structures has emerged as a promising therapy for depression. Two techniques, in particular—transcranial magnetic stimulation (TMS) and electrical deep brain stimulation (DBS)—have garnered substantial empirical support. These techniques have been used to target the dlPFC and vmPFC, respectively, and the clinical outcomes confirm the importance of these areas in the pathophysiology of depression.

In TMS, a small coil held near the scalp generates a magnetic field that induces an electric field in the underlying areas of the brain. With the appropriate frequency and intensity of stimulation, TMS can be used to non-invasively excite the underlying cortex. Dozens of studies have investigated the efficacy of left dlPFC stimulation in treating refractory depression, with most reporting a statistically significant reduction in depressive symptoms [26,27].

Unlike TMS, which can only be used to directly affect the activity of outer cortex, DBS can be used to manipulate the activity of interior brain structures, such as vmPFC. In a pioneering study of this technique, surgically implanted electrodes were used to chronically inhibit the white matter underlying subgenual cortex of six patients with severe refractory depression [12]. Four of the six patients exhibited a sustained remission of depression. The locus of DBS in this study was adjacent to and interconnected with the vmPFC area previously described in functional imaging and lesion studies, and in close proximity to the site of subcaudate tractotomy.

The development of focal brain stimulation techniques such as DBS and TMS builds on and converges with the previously reviewed functional imaging and lesion patient literature. The reduction in depression observed through TMS-induced excitation of dlPFC follows from functional imaging studies, which associate depression with dlPFC hypoactivity and the recovery from depression with increased dlPFC activity, and from lesion studies, which associate dlPFC lesions with increased depression severity. Likewise, the reduction in depression observed through DBS-induced inhibition of vmPFC follows from functional imaging studies, which associate depression with vmPFC hyperactivity and the recovery from depression with decreased vmPFC activity, and from lesion studies, which associate vmPFC lesions with decreased depression severity.

6. Discussion: roles of dlPFC and vmPFC in depression

Taken together, the results from functional imaging, lesion patient, and brain stimulation studies provide convergent and compelling evidence that dlPFC and vmPFC play critical, yet distinct, roles in the pathophysiology of depression. The essentially opposite pattern of results for vmPFC and dlPFC begs the question: What are the neurocognitive/neurobehavioral mechanisms by which vmPFC and dlPFC mediate depression? In other words, how is the function of each PFC subregion related to depression?

First we consider the role of vmPFC in depression. One possibility is that vmPFC plays a basic role in the generation of negative emotion. Functional imaging data indicate that resting vmPFC activity is correlated with the subjective experience of negative affect [28], and vmPFC damage is associated with blunted autonomic responses to emotionally arousing pictures [29]. Perhaps vmPFC coordinates the physiological components of negative emotion through its projections to periaqueductal gray, hypothalamus, and amygdala [7]. An alternative possibility is that vmPFC's role in depression is related to self-awareness or self-reflection. Previous lesion studies associate vmPFC damage with a loss of self-insight [30,31], as well as a marked reduction in certain types of negative affect, particularly shame, guilt, embarrassment, and regret [31–33]. One common feature of these emotions is that they all involve an element of self-awareness or self-reflection. Data from our lesion study of depression further support this idea: patients with bilateral vmPFC lesions reported conspicuously low levels of "cognitive/affective" symptoms (such as guilt, self-dislike, and sadness) but normal levels of "somatic" symptoms (such as fatigue and changes in sleeping or appetite) [20]. Because the "cognitive/affective" items ostensibly involve a greater degree of self-reflection and rumination than the "somatic" items, one could conceive of the vmPFC patients' selective reduction in depressive symptoms as a secondary effect of a primary lack of self-awareness and self-reflection.

Next we consider the role of dlPFC in depression. As we mentioned earlier, dlPFC has primarily been associated with "cognitive" or "executive" functions, such as the maintenance and manipulation of items working memory, intention formation, goal-directed action, abstract reasoning, and attentional control [34]. However, recent studies suggest that dlPFC-mediated cognitive control functions may also pertain to emotion. Specifically, functional imaging studies demonstrate the recruitment of dlPFC during the regulation of negative emotion through reappraisal/suppression strategies [35–39]. We believe the results reviewed here are consistent with these findings; if the reappraisal/suppression of negative affect is a protective mechanism against depression, and if dlPFC is the key neural substrate for this function, then one would expect dlPFC to play a critical role in depression. Thus, a defect in the regulation

of negative affect due to dlPFC dysfunction is indeed a plausible mechanism for dlPFC's involvement in depression.

7. Summary and conclusion

As we have reviewed here, a large and growing body of research implicates the ventromedial and dorsolateral sectors of prefrontal cortex as key neural substrates underlying depression. Functional imaging studies associate depression with opposite patterns of activity in these areas: hypoactivity in dlPFC but hyperactivity in vmPFC. Similarly, lesion studies demonstrate opposite effects of damage to these areas on depression: dlPFC lesions exacerbate depressive symptoms whereas vmPFC lesions diminish depressive symptoms. Finally, brain stimulation studies suggest opposite strategies for the therapeutic manipulation of electrophysiological activity in these areas: TMS-mediated excitation of dlPFC but DBS-mediated inhibition of vmPFC. In conclusion, the neuroscientific study of prefrontal subregions in depression has included basic, translational, and clinical research approaches, yielding synergistic progress toward a more complete understanding of the pathophysiological mechanisms and more effective treatment options.

Acknowledgement

This work was supported in part by the National Institute of Neurological Disorders and Stroke intramural research program, DAMD17-01-1-0675 (J.G.).

References

- Davidson RJ, Pizzagalli D, Nitschke JB, Putnam K. Depression: perspectives from affective neuroscience. *Annu Rev Psychol* 2002;53:545–74.
- Drevets WC. Functional neuroimaging studies of depression: the anatomy of melancholia. *Annu Rev Med* 1998;49:341–61.
- Drevets WC. Orbitofrontal cortex function and structure in depression. *Ann NY Acad Sci* 2007;1121:499–527.
- Kringelbach ML, Rolls ET. The functional neuroanatomy of the human orbitofrontal cortex: evidence from neuroimaging and neuropsychology. *Prog Neurobiol* 2004;72(5):341–72.
- Rosenkilde CE. Functional heterogeneity of the prefrontal cortex in the monkey: a review. *Behav Neural Biol* 1979;25(3):301–45.
- Zald DH. Orbital versus dorsolateral prefrontal cortex: anatomical insights into content versus process differentiation models of the prefrontal cortex. *Ann NY Acad Sci* 2007;1121:395–406.
- Ongur D, Price JL. The organization of networks within the orbital and medial prefrontal cortex of rats, monkeys and humans. *Cereb Cortex* 2000;10(3):206–19.
- Barbas H. Connections underlying the synthesis of cognition, memory, and emotion in primate prefrontal cortices. *Brain Res Bull* 2000;52(5):319–30.
- Drevets WC, Videen TO, Price JL, Preskorn SH, Carmichael ST, Raichle ME. A functional anatomical study of unipolar depression. *J Neurosci* 1992;12(9):3628–41.
- Biver F, Goldman S, Delvenne V, Luxen A, De Maertelaer V, Hubain P, et al. Frontal and parietal metabolic disturbances in unipolar depression. *Biol Psychiatry* 1994;36(6):381–8.
- Greicius MD, Flores BH, Menon V, Glover GH, Solvason HB, Kenna H, et al. Resting-state functional connectivity in major depression: abnormally increased contributions from subgenual cingulate cortex and thalamus. *Biol Psychiatry* 2007;62(5):429–37.
- Mayberg HS, Lozano AM, Voon V, McNeely HE, Seminowicz D, Hamani C, et al. Deep brain stimulation for treatment-resistant depression. *Neuron* 2005;45(5):651–60.
- Baxter Jr LR, Schwartz JM, Phelps ME, Mazziotta JC, Guze BH, Selin CE, et al. Reduction of prefrontal cortex glucose metabolism common to three types of depression. *Arch Gen Psychiatry* 1989;46(3):243–50.
- Galyner II, Cai J, Ongseng F, Finestone H, Dutta E, Sersen D. Hypofrontality and negative symptoms in major depressive disorder. *J Nucl Med* 1998;39(4):608–12.
- Brody AL, Saxena S, Mandelkern MA, Fairbanks LA, Ho ML, Baxter LR. Brain metabolic changes associated with symptom factor improvement in major depressive disorder. *Biol Psychiatry* 2001;50(3):171–8.
- Mayberg HS, Liotti M, Brannan SK, McGinnis S, Mahurin RK, Jerabek PA, et al. Reciprocal limbic-cortical function and negative mood: converging PET findings in depression and normal sadness. *Am J Psychiatry* 1999;156(5):675–82.
- Mayberg HS, Brannan SK, Tekell JL, Silva JA, Mahurin RK, McGinnis S, et al. Regional metabolic effects of fluoxetine in major depression: serial changes and relationship to clinical response. *Biol Psychiatry* 2000;48(8):830–43.
- Wagner G, Sinsel E, Sobanski T, Kohler S, Marinou V, Mentzel HJ, et al. Cortical inefficiency in patients with unipolar depression: an event-related fMRI study with the Stroop task. *Biol Psychiatry* 2006;59(10):958–65.
- Harvey PO, Fossati P, Pochon JB, Levy R, Lebastard G, Lehericy S, et al. Cognitive control and brain resources in major depression: an fMRI study using the n-back task. *Neuroimage* 2005;26(3):860–9.
- Koenigs M, Huey ED, Calamia M, Raymond V, Tranel D, Grafman J. Distinct regions of prefrontal cortex mediate resistance and vulnerability to depression. *J Neurosci* 2008;28(47):12341–8.
- Ellenbogen JM, Hurford MO, Liebeskind DS, Neimark GB, Weiss D. Ventromedial frontal lobe trauma. *Neurology* 2005;64(4):p757.
- Newcombe R. The lesion in stereotactic subcaudate tractotomy. *Br J Psychiatry* 1975;126:478–81.
- Bridges PK, Bartlett JR, Hale AS, Poynton AM, Malizia AL, Hodgkiss AD. Psychosurgery: stereotactic subcaudate tractotomy. An indispensable treatment. *Br J Psychiatry* 1994;165(5):599–611 [discussion 612–3].
- Goktepe EO, Young LB, Bridges PK. A further review of the results of stereotactic subcaudate tractotomy. *Br J Psychiatry* 1975;126:270–80.
- Sachdev PS, Sachdev J. Long-term outcome of neurosurgery for the treatment of resistant depression. *J Neuropsychiatry Clin Neurosci* 2005;17(4):478–85.
- Marangell LB, Martinez M, Jurdi RA, Zboyan H. Neurostimulation therapies in depression: a review of new modalities. *Acta Psychiatr Scand* 2007;116(3):174–81.
- Loo CK, Mitchell PB. A review of the efficacy of transcranial magnetic stimulation (TMS) treatment for depression, and current and future strategies to optimize efficacy. *J Affect Disord* 2005;88(3):255–67.
- Zald DH, Mattson DL, Pardo JV. Brain activity in ventromedial prefrontal cortex correlates with individual differences in negative affect. *Proc Natl Acad Sci U S A* 2002;99(4):2450–4.
- Damasio AR, Tranel D, Damasio H. Individuals with sociopathic behavior caused by frontal damage fail to respond autonomically to social stimuli. *Behav Brain Res* 1990;41(2):81–94.
- Barrash J, Tranel D, Anderson SW. Acquired personality disturbances associated with bilateral damage to the ventromedial prefrontal region. *Dev Neuropsychol* 2000;18(3):355–81.
- Beer JS, John OP, Scabini D, Knight RT. Orbitofrontal cortex and social behavior: integrating self-monitoring and emotion-cognition interactions. *J Cogn Neurosci* 2006;18(6):871–9.
- Camille N, Coricelli G, Sallet J, Pradat-Diehl P, Duhamel JR, Sirigu A. The involvement of the orbitofrontal cortex in the experience of regret. *Science* 2004;304(5674):1167–70.
- Koenigs M, Young L, Adolphs R, Tranel D, Cushman F, Hauser M, et al. Damage to the prefrontal cortex increases utilitarian moral judgements. *Nature* 2007;446(7138):908–11.
- Miller EK, Cohen JD. An integrative theory of prefrontal cortex function. *Annu Rev Neurosci* 2001;24:167–202.
- Ochsner KN, Bunge SA, Gross JJ, Gabrieli JD. Rethinking feelings: an fMRI study of the cognitive regulation of emotion. *J Cogn Neurosci* 2002;14(8):1215–29.
- Ochsner KN, Ray RD, Cooper JC, Robertson ER, Chopra S, Gabrieli JD, et al. For better or for worse: neural systems supporting the cognitive down- and up-regulation of negative emotion. *Neuroimage* 2004;23(2):483–99.
- Levesque J, Eugene F, Joannette Y, Paquette V, Mensour B, Beaudoin G, et al. Neural circuitry underlying voluntary suppression of sadness. *Biol Psychiatry* 2003;53(6):502–10.
- Phan KL, Fitzgerald DA, Nathan PJ, Moore GJ, Uhdé TW, Tancer ME. Neural substrates for voluntary suppression of negative affect: a functional magnetic resonance imaging study. *Biol Psychiatry* 2005;57(3):210–9.
- Eippert F, Veit R, Weiskopf N, Erb M, Birbaumer N, Anders S. Regulation of emotional responses elicited by threat-related stimuli. *Hum Brain Mapp* 2007;28(5):409–23.